

Case study: Chronic nonhealing surgical wound

Contributed by Dr. Nooshin Zolfaghari,
DPM, CWS, MPH

Smith+Nephew

Collagenase
SANTYL[◇]
Ointment 250 units/gram

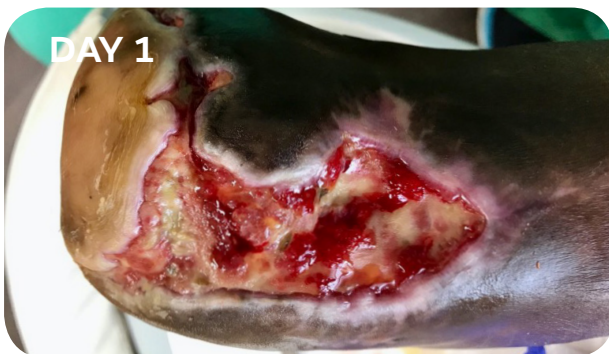
Patient

A 54-year-old male patient with a past medical history of type 2 diabetes mellitus, hypertension, and peripheral vascular disease. Patient underwent a trans-metatarsal amputation (TMA) due to developing osteomyelitis from infected non-healing diabetic ulcer. He was seen weekly in office post TMA for wound care.

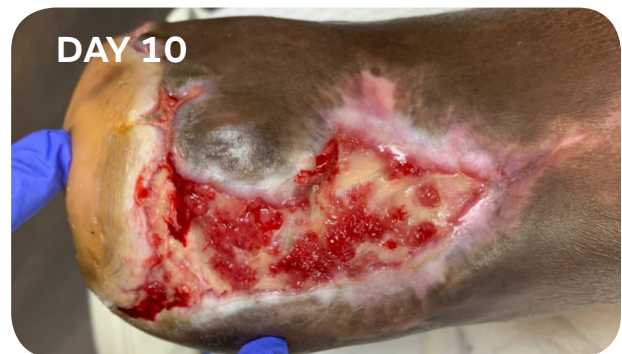Wound presentation

Wound measuring 11.0cm x 5.0cm x 0.2cm located at the dorsal distal aspect of right foot, at the TMA surgical site. Wound with yellowish, fibrotic, moist tissue with moderate serosanguineous drainage.

Treatment




- Cleansed the wound with normal saline and sharp debridement using sterile No. 15 blade
- SANTYL Ointment was applied to the wound followed by Hydrofera Blue™ and dry sterile dressings
- Daily dressing changes were ordered for home health care



- Cleansing the wound with normal saline and sharp debridement using sterile No. 15 blade
- SANTYL Ointment was applied to the wound followed by Hydrofera Blue™ and dry sterile dressings
- Continue daily wound care dressing changes for home health care
- Measures 10.5cm x 4.5cm x 0.1cm

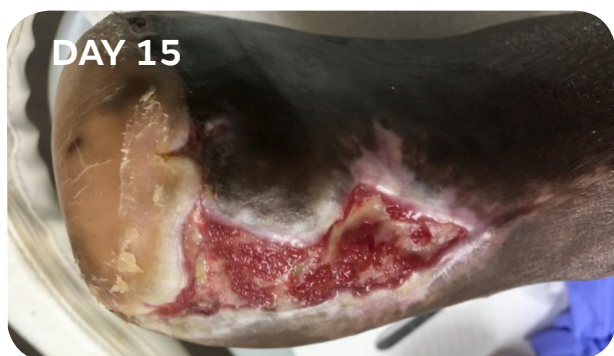


Product
compatibility

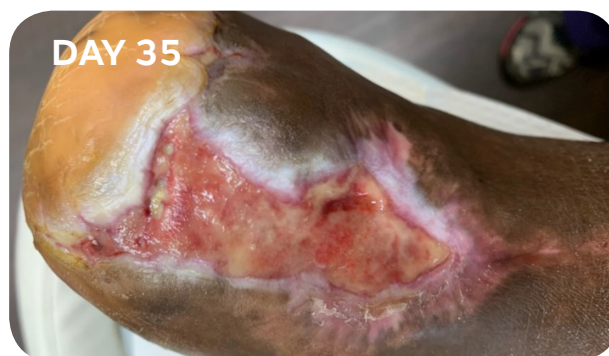


Dosing
calculator

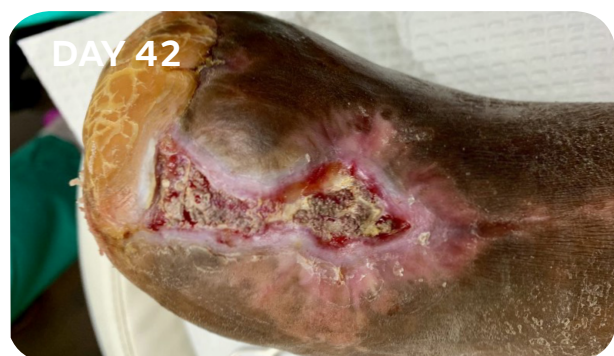Treatment



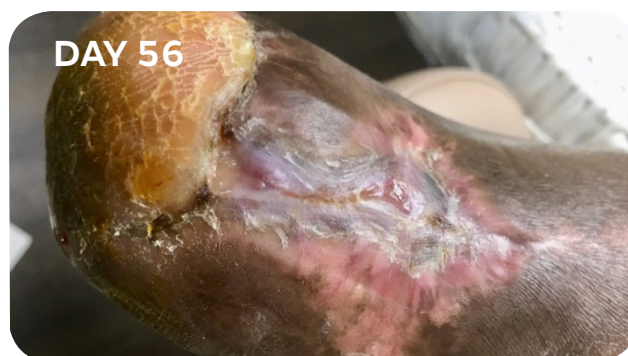- Cleansing the wound with normal saline and sharp debridement using sterile No. 15 blade
- SANTYL^o Ointment was applied to the wound followed by Hydrofera Blue™ and dry sterile dressings
- Continue daily wound care dressing changes for home health care
- Measures 9.0cm x 3.3cm x 0.1cm



- Cleansing the wound with normal saline and sharp debridement using sterile No. 15 blade
- SANTYL Ointment was applied to the wound followed by Hydrofera Blue™ and dry sterile dressings
- Continue daily wound care dressing changes for home health care
- Measures 7.5cm x 2.5cm x 0.1cm



- Cleansing the wound with normal saline and sharp debridement using sterile No. 15 blade
- SANTYL Ointment was applied to the wound followed by Hydrofera Blue™ and dry sterile dressings
- Continue daily wound care dressing changes for home health care
- Measures 4.5cm x 1.5cm x 0.0cm



- Wound site completely closed
- Area is clean dry and fully intact in 8 weeks

Important Safety Information

Indications: Collagenase SANTYL Ointment ("SANTYL") is a prescription-only medication indicated for debriding chronic dermal ulcers and severely burned areas. **Contraindications:** SANTYL is contraindicated in patients who have shown local or systemic hypersensitivity to collagenase. **Warning and Precautions:** The optimal pH range of collagenase is 6 to 8. Higher or lower pH conditions will decrease the enzyme's activity and appropriate precautions should be taken. The enzymatic activity is also adversely affected by certain detergents, and heavy metal ions such as mercury and silver which are used in some antiseptics. As such, the wound should be properly cleansed prior to application of SANTYL. Debilitated patients should be closely monitored for systemic bacterial infections because of the theoretical possibility that debriding enzymes may increase the risk of bacteremia. A slight transient erythema has been noted occasionally in the surrounding tissue, particularly when SANTYL was not confined to the wound. SANTYL is not indicated for wound closure. Discontinue use of SANTYL after granulation tissue is well-established. **Adverse Reactions:** No allergic sensitivity or toxic reactions have been noted in clinical use when used as directed. The risk information provided herein is not comprehensive. For complete prescribing information, please refer to the accompanying PI or visit: <https://santyl.com/sites/default/files/2019-12/SANTYL-PI.pdf>. You are encouraged to report negative side effects of prescription drugs to FDA. Visit MedWatch or call 1-800-FDA-1088.

Results

Consistency in weekly sharp debridement and daily wound care dressings with SANTYL Ointment aided in successful resolution of a chronic TMA wound in 2 months.

Individual results may vary.